

BRAIN TUMOR DETECTION IN TELERADIOLOGY USING HARD THRESHOLDING

Suchitra K¹, Vineel Kumar Reddy I², Venkata Naresh M³

Abstract- Tele-radiology is an emerging stream of medical diagnosis. In which the Process of Detecting Brain tumors from patient MRI report is a critical issue, the tumor detection is often a preliminary phase. We are implementing a technique to detect brain tumor and its severity based on the size of the tumor by using hard thresholding. The proposed technique can be efficiently applied to detect and identify the brain tumor from MRI images of patient. We are also evaluating the computational complexity of the proposed algorithm through elapsing time; the data set which we are taking is a DICOM standard. It proves to be a handy mechanism for the physicians to detect, locate and identify the size of tumor.

Keywords – Brain Tumor, Magnetic Resonance Imaging (MRI), DICOM Format Images, Edge Detection, Filtering, Thresholding, Segmentation.

1. INTRODUCTION

Any unwanted and abnormal growth of a tissue is known as TUMOUR. BRAIN TUMOUR is a type of tumour in which different brain cells grow in uncontrolled and abnormal manner. Normal mechanism of the controlled cell differentiation has failed in these cases. BRAIN TUMOURS are of TWO types. They are:

1. Primary brain tumours
2. Metastatic brain tumours

Sl.no	Parameters	Primary	Metastatic
1	Origin	Arise from the central nervous system. That is brain and spinal cord.	Arise from any organ in the body
2	Tumour region	Most of the times stay Within the CNS.	Spread to other parts of the body.
3	Age group	It can occur in any age group. But more Commonly seen in children and old age people.	Most commonly it occurs in adults that age groups >55 years
4	Types of tumours	1. Benign 2. Malignant	1. Skin cancer 2. Lung cancer 3. Stomach cancer

Figure 1. Differences in primary and metastatic tumours

1.1 Primary brain tumours may be BENIGN OR MALIGNANT

Any tumour that starts with in the brain is a primary brain tumour. It can cause various problems such as pressure over the adjacent normal brain tissue causing several neurological deficits.

Metastatic brain tumours are the tumours which occur in the brain secondary to the spread of the metastatic cells of the cancer cells from other part of the body. Metastatic brain tumours are always MALIGNANT. Each radiologist analyse differently. So, human intervention is difficult in detecting the brain tumours. Automation systems helps in effective detection of the brain tumours. Transmission of radiological images such as X-rays, CT-scans and MRI from one location to the other for sharing with other physicians and radiologists through interconnectivity of the computer systems is called TELERADIOLOGY. Every year growth of the radiologist physicians is around 2%. But, the growth of the imaging procedures is 15%. Thus teleradiology helps in decreasing the time consumed in transferring the radiological images manually

2. LITERATURE SURVEY

In a study done by Halder et al in the year 2012 with the title, Image segmentation approach by using object labeling algorithm of K-means clustering method. The drawbacks found to be are very poor detection at boundaries. In a study done

¹ Student, Department of ECE, Sree Vidyanikethan Engineering College Tirupati

² Student, Department of ECE, Sree Vidyanikethan Engineering College Tirupati

³ Asst. Professor, Department of ECE, Sree Vidyanikethan Engineering College Tirupati

by Preethi and suresh, in the year 2014, with the title, Image segmentation approach by using Fuzzy C-means clustering algorithm. High complexity is the drawback of this method.

In a study done by Abdel Maksoud et al in the year 2015 with the title Image segmentation approach by using k-means clustering method deals with fuzzy C-means algorithm. In this study it has found about few drawbacks of the method. These are less segmentation quality and more processing time. The above studies show the drawbacks of the above methods. So, to overcome these drawbacks, we implement OTSU image segmentation.

By implementing OTSU image segmentation [2] and thresholding levels of images, the computational time decreases compare to k-means clustering for image segmentation.

Object labelling algorithm of K-means clustering method [3] can be implemented on MRI images. It also involves some methods in it like median filtering and morphological for tumour detection. In this we use Watershed algorithm with OTSU image segmentation using real time MRI images [1] standard like DICOM.

3. PROPOSED METHOD

3.1 Watershed Algorithm

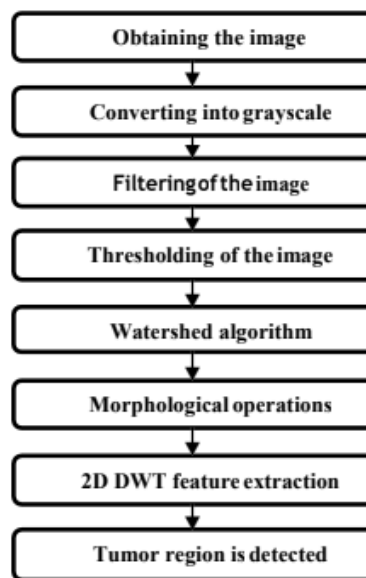
Watershed algorithm is used in image process primarily for segmentation purposes. This algorithm can be used if the foreground and background of the image can be identified.

3.2 MERITS:

It works best to capture the weak edges

Watershed algorithm improves the primary results of segmentation of tumour done by k-means.

3.3 FLOWCHART:



3.3.1 Obtaining the image:

When person undergoes MRI scan, the MRI image is stored in the data base. Thus, the image of the patient is obtained. Usually MRI images look black and white

3.3.2 Converting in to grayscale image:

Grayscale image contains only brightness information. In a grayscale image, the pixel value corresponds to an amount or intensity or quality of light. Each pixel is represented by a byte based on brightness graduation. 0 to 255 is the variation of brightness in a 8-bit image. 0 represents black and 255 represents white.

3.3.3 Filtering of the image:

High pass filter is applied to the image in order to remove the noise, improve the quality of the image and to reduce the miscalculation. The impulse noise is removed with help of application of median filter. Median filters provide excellent noise reduction capabilities. Blurring is considerably less than linear smoothing filters of similar size. So median filters are popular

3.3.4 Thresholding of the image:

By selecting thresholding value T , the objects are extracted from the background. Object point is any point on (x,y) in the image at which $f(x,y) > T$. otherwise the point is called background point. Global thresholding is when the T constant is

applicable over the entire image. Variable thresholding or local regional thresholding are when the T value changes over the image. Adaptive thresholding is when T depends on the spatial co-ordinates (x,y).

3.3.5 Applying morphological operations:

Dilation and erosion is the morphological operation. Using vector addition dilation combines two sets. Using vector subtraction, erosion combines two sets and is the dual operator of dilation. Both are not invertible transforms.

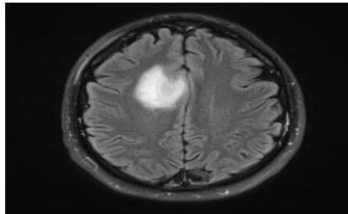
3.3.6 Tumour region detection:

After using thresholding technique and then by application of morphological operation on the MRI image, tumour region is detected.

4. RESULTS AND DISCUSSIONS

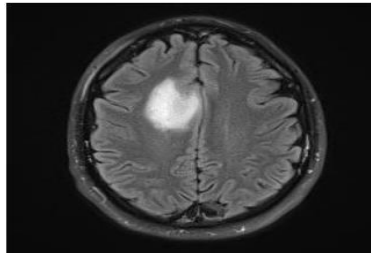
4.1 Obtaining the image

The MRI image can be obtained from the patient's data base on the computer when the person undergoes the MRI scanning. Usually MRI images looks like a black and white images.



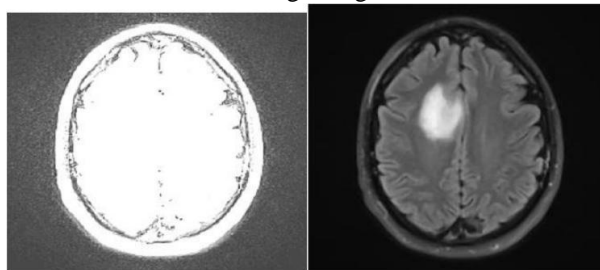
4.2. Converting into grayscale image

Grayscale images are the images that contain only brightness information. Each pixel value in a grayscale image corresponds to an amount or quantity or intensity of light.



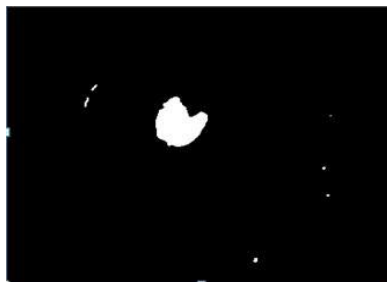
4.3. Filtering of the image

Image which is applied to the high pass filter to remove the noise present so as to improve the image quality and to reduce the miscalculation and with the help of the median filter, the image is again filtered so as to remove the impulse noise.




4.4. Thresholding of the image

Thresholding is used to extract the objects from the background by selecting a threshold value T.




4.5. Watershed algorithm

This segmentation technique is particularly useful to segment objects when they are touching each other. This algorithm helps in finding the catchment basins and ridge lines in the image.



4.6. Morphological Operations

Morphological operation involves dilation and erosion. Dilation combines two sets using vector addition. Erosion combines two sets using vector subtraction and is the dual operator of dilation. Both are not invertible transforms.



4.7. Tumor region is detected

Tumor region detection is done by using thresholding technique and then by applying morphological operation on the image.

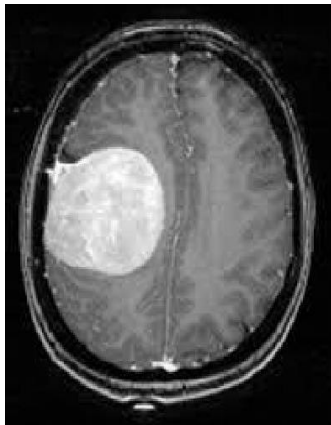


Image 1

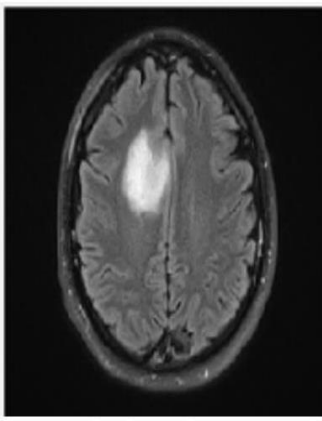


Image 2

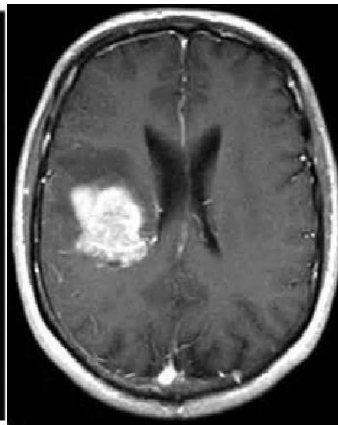

Image 3

SL.NO	BY OTSU METHOD		BY WATERSHED METHOD	
	Total time (sec)	Self time(sec)	Total time (sec)	Self time(sec)
Image 1	20.2809	0.914	17.965	0.6082
Image 2	18.1462	0.892	15.469	0.5993
Image 3	17.9984	0.798	15.265	0.5373

5. REFERENCES

- [1] E.-S.A El-Dahshan, T. Hosny, and A.-B.M. Salem, "Hybrid Intelligent Techniques for MRI Brain Images Classification," Digital Signal Processing, vol 20, pp: 433441, 2010.
- [2] Salim Lahmiri., Mounir Boukadoum," Classification of brain MRI using the LH and HL wavelet transform sub- bands", In proceeding of: International Symposium on Circuits and Systems (ISCAS 2011) , Rio de Janeiro, Brazil,1025-1028,2011.
- [3] V.P,Gladi Pushpa Rathi., Dr.S,Palani,"Brain Tumor Mri Image Classification With Feature Selection And Extraction Using Linear Discriminant Analysis", International Journal of Information Sciences and Techniques (IJIST), Vol.2, No.4 ,131-146,2012.
- [4] S. Beuther and F. Meyer, "The morphological approach to sewn entation: the watershed transformation," in Mathematical Morphology and Its Applications to Image Processing, E. it Dougherty, Ed., vol. 34, pp. 433-481, Marcel Dekker, New York, NY, USA, 1993.
- [5] P. R. Hill, C. N. Canaga•ajah, and D. R. Bull, "Image segmentation using a.texture gadiant based watershed transform," WEE Transactions on Image Processing, vol. 12, no. 12, pp. 1618-1633, 2003.